

Fibrothecoma of Ovary

B Pratyusha¹, Anandam G², Sharadrutha³

¹Postgraduate Student, ²Professor and Head, ³Professor, Department of Pathology, Prathima Institute of Medical Sciences, Karimnagar, Telangana, India.

Address for correspondence: Dr B Pratyusha, Postgraduate Student, Department of Pathology, Prathima Institute of Medical Sciences, Nagunur, Karimnagar, Telangana, India.

Email: pbudaraju88@gmail.com

ABSTRACT

Ovarian fibrothecomas represent an ovarian stromal neoplasm developing in a wide spectrum of clinical settings. Fibrothecomas have been described as rare neoplasms. The clinical presentation of ovarian fibrothecoma is relatively nonspecific such as pelvic and abdominal pain or distension; however, ovarian fibromas may be accompanied by two associations. The first is called Meig's syndrome (ovarian fibroma, hydrothorax and ascites). The second association is with basal cell nevus syndrome (bilateral ovarian fibromas, multiple basal cell carcinoma of skin, odontogenic keratocysts, etc.). Here we present an unusual clinical manifestation of ovarian fibrothecoma in a young female who presented with massive abdominal distension and significant weight loss in a duration of one month. Due to these clinical features, it has to be differentiated from massive edema of ovary, sclerosing tumor of ovary and any other ovarian or abdomino-pelvic malignancies.

Keywords: Fibrothecoma, ovary, massive edema, sclerosing tumor, Meig's syndrome

INTRODUCTION

Both thecoma and fibroma are included in stromal tumors of ovary. Thecomas are histologically composed of lipid containing cells that resemble theca interna cells. Fibromas are composed almost entirely of round to spindle shaped cells, forming variable amounts of collagen. The differentiation between thecomas and fibromas is occasionally imprecise because of the overlap of histological and immunohistochemical features. The term 'fibrothecoma' has been used in such circumstances^{1,2}. These are rare neoplasms and constitute about 4% of all ovarian tumors. Ovarian tumors of this group have been reported to show myxoid degeneration and frequently show focal or partial cystic degeneration. These tumors can present with varied clinical features which may mimic malignancies.

CASE REPORT

An 18 year old female presented with abdominal distension and mild constipation of 1 month duration. She had

lost 10% of body weight in one month. Ascites was present. However, this was not a case of Meig's syndrome as there was no hydrothorax. All relevant lab studies were done. USG findings showed a large hypoechoic lesion arising from the pelvis, measuring 13x16 cm, reaching upto the umbilicus. The patient underwent exploratory laparotomy, which revealed right sided ovarian tumor measuring 14x16 cm. Complete removal of tumor mass was done. Histomorphological study of tumor revealed a fibrothecoma. No malignant changes were observed in the tumor.

DISCUSSION

Stromal tumors of the ovary include thecomas and fibromas; but differentiation between the two may be difficult due to histological and immunohistochemical overlap of features between them. Hence, the term 'fibrothecoma' has been used frequently. The exact incidence of fibrothecomas varies in different studies, although they have been described as rare neoplasms^{3,4}. Several studies have shown that both granulosa and theca cell tumors of ovary have a common mesenchymal origin and because of this common mesenchymal stem cell origin, a tumor with an admixture of both these type of cells is not surprising. Here we present an unusual clinical manifestation of fibrothecoma with abdominal distention in a young female.

A fibrothecoma with atypical ultrasonographic appearance may be mistaken for malignancy, particularly if associated with fluid in the pouch of Douglas or ascites as in the present case.

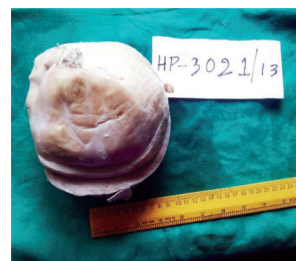


Figure 1



Figure 2

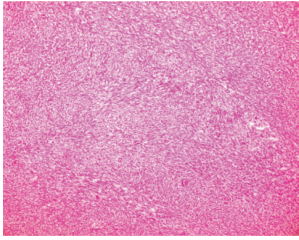


Figure 3

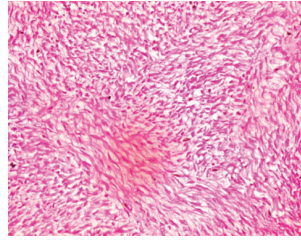


Figure 4

Figures 1 & 2: Grossly, the resected ovarian mass measured 14x16x10 cm (Fig.1). Cut section was firm, grayish white with a fascicular pattern and a few yellow areas (Fig.2). Normal ovarian tissue was not identified.

Figures 3 & 4: On microscopy, the ovarian tumor mass was composed of spindled stromal cells which were randomly distributed and arranged in a fascicular pattern (Fig.3). An appreciable amount of the mass was also composed of thecal cells which were oval to rounded with moderate to abundant pale, vacuolated cytoplasm. The nuclei were round to oval with little atypia. The fibrous component could be seen separating the sheets and nests of theca cells (Fig.4).

The ovarian mass in the present case demonstrated both spindle cells associated with collagen bundles and lipid laden cells with a box-in appearance representing both thecoma and fibroma respectively. Therefore, the histological findings in the present case were consistent with a diagnosis of 'fibrothecoma'.

CONCLUSION

Ovarian fibrothecomas are uncommon tumors of gonadal stromal cell origin accounting for 3–4% of all ovarian tumors. They are rarely malignant and in 90% of the cases are unilateral. Ovarian fibrothecomas represent an ovarian stromal neoplasm occurring in a wide spectrum of clinical settings. Ovarian fibromas may be seen in association with Meig's syndrome or basal cell nevus syndrome⁴. If there is a past history of an oophorectomy at the time of presentation, then status of ovaries must always be assessed whenever a pelvic pathology is suspected. We are presenting this case due to the rarity of its nature and its unusual presentation in a young female.

REFERENCES

1. Scully R E, Youg R H, Clement P B. Tumors of the ovary, maldeveloped gonads, fallopian tube and broad ligament. Washington DC, AFIP, 1996; 189-201.
2. Samanth KK, Black WC. Benign ovarian stromal tumors associated with free peritoneal fluid. Am J Obstet Gynecol 1970; 107: 538-545.
3. Costa MJ, Morris R, DeRose PB, Cohen C. Histological and immunohistochemical evidence for considering ovarian myxoma as a variant of the thecoma-fibroma group of ovarian stromal tumors. Arch Pathol Lab Med 1993; 117: 802-808.
4. Suprabha Sharma, R Bansal, Sanjay Upreti, Anjali Khare, Sangeeta Sharma, Deepti Agarwal; Ovarian Fibrothecoma with Extensive Cystic Degeneration: Two Case Reports. Indian Journal of Clinical Practice, 2013 May; 23(12): 840-841.

How to cite this article : Pratyusha B, Anandam G, Sharadrutha. Fibrothecoma of Ovary. Perspectives in Medical Research 2017;5(2):65-66.

Sources of Support: Nil, Conflict of interest: None declared.